


STATEMENT

DESMOND BRAMICH DATE OF BIRTH



- 1 I am a legally qualified medical practitioner registered in Queensland as such and as a specialist pathologist
- 2 Desmond Bramich was admitted to the Bundaberg Base Hospital on 25 -07 -2004 and died there on 28 -07 -2004. I performed a Post Mortem Examination on 29 -07 -2004 and ~~prepare~~ prepared reports
- 3 I am not a Specialist Thoracic Physician or Surgeon and did not see or examine Mr Bramich before or during his last period of life, in the hospital. The opinions given are, therefore, in the nature of an overview. It is easy to be wise after the event.
- 4 The nature of the accident involving heavy crushing could mean that it could be difficult to estimate the degree of internal damage and external signs and symptoms could minimize the seriousness of the situation
- 5 Aging persons may present with blunted clinical responses to haemorrhage /infection, etc. Initially, the changes in Blood Pressure and Pulse were not dramatic but the Blood Pressure was depressed for an hypertensive man. Pulse somewhat raised and Haemoglobin lowered.
- 6 The full extent of slow on-going bleeding was probably not appreciated and might in part have been due to the chest tube (s) getting blocked or misplaced. Also, there seems to have been a false sense of security by the apparent well-being of Mr Bramich on 26-07-2004. Mobilization and physiotherapy may have been a little too vigorous depending upon what was done: Gentle coughing to try and clear ~~sex~~ secretions would be necessary.
- 7 A large quantity of blood accumulated and clotted in the Right Pleural Space over the period until the hypovolaemia (reduced circulating blood volume) became critical and gas exchange imperilled by the collapsed compressed Right Lung. Hypovolaemic Shock, Left Ventricular Failure with Cardio-Respiratory Failure ensued

8 Devoted and Heroic attempts with plans for transfer- retrieval were made but by this time, he was beyond help

9 Injuries to the Thorax, particularly those incorporating crushing, can be very difficult to manage because of damage to the soft tissues as well as fracturing, etc. In this context, it might have been appropriate to consider early transfer to a specialist centre. Surgery may or may not have helped; bleeding points might have been able to be identified, then. However, the outcome could still have been disappointing.

10 I have read the hospital notes initially briefly and with more leisure recently. The progress notes are rather sparse though sufficient. The final-agonal- notes are full. Appropriate observations and tests were carried out. It is not clear who or how decisions were made - i.e. - the senior person in charge.

II In Summary: a difficult case to judge the best and safest course of action. It may be that the seriousness of the internal damage and the continuing bleeding were not fully realized early. Was an earlier transfer or surgical intervention considered? However, whatever course of action, I think it doubtful that a survival would have been achieved

R R ASHBY

04 - 03 - 2005

Rosemary Ashby

Form 8
 QUEENSLAND
 CORONERS ACT 2003
 (Section 25)
 AUTOPSY REPORT

✓ TYPED REPORT TO FOLLOW

AUTOPSY REPORT		Authorisation: A. D. BARRETT	Autopsy No:
Date and place of death: 28/07/04 BUNDABERG		Given name/s: DESMOND	Client Reference No. BRAMICH
Time, date and place of autopsy examinations: 1410. 29/07/04 BUNDABERG MORGUE		Sex, age, Date of Birth: M 56 15/04/1948	

ORDERS MADE BY CORONER:

TYPE OF EXAMINATION REQUIRED:

- External only Date ordered: _____
- External Date ordered: _____ and _____
- Partial Internal of: _____ Date ordered: _____
- External Date ordered: _____ and _____
- Full Internal: _____ Date ordered: 28/07/2004

02 AUG 2004
 BUNDABERG

TESTS ORDERED BY CORONER:

TOXICOLOGY HISTOLOGY

DEATH SCENE

AS PER FORM 1.

OBSERVERS PRESENT

CONSTABLE C. FINDLAY. DR BOYD DR GUPTA - SURGICAL REGISTRARS

EXTERNAL EXAMINATION:

Identifying features:

PHOTO. BODY TAGS. TATTOO ROSE MOTIF L. CHEST.

Clothing/Jewellery/other material

IN BAG CONTAINING BLOOD. GREY & WHITE CHECK HOSPITAL UNDER PANTS

Physical characteristics

STOCKY MUSCULAR MID AGE CAUCASIAN MAN. HT 180cm. GREY HAIR. GREY EYES. CIRCUMCIZED.

Extremities

PALE.

Signs of post mortem change

RESIDUAL RIGOR MORTIS. FAINT DORSAL LIVIDITY.

Signs of recent therapy

ECG PADS CV MONITOR. IV LINES ARMS. 2 CHEST TUBES R. 1 LEFT. EPICARDIAL PUNCTURE MARKS. BLADDER CATHETER

Signs of recent injury

BRUISING R CHEST R UPPER BACK & MID BACK & UPPER CHEST & SHOULDER. BLOOD STAINED FLUID IN MOUTH AND Oozing

FROM TUBE SITES. VERY PALE.

STO

INTERNAL EXAMINATION (if applicable) TISSUES PALE AND OEDEMATOUS

Head (Scalp, Skull, Meninges, Brain, Spinal cord, Tongue)

SKULL PALE. SKULL INTACT. BRAIN PALE 1400G NO LESIONS. SPINAL CORD INTACT. TONGUE CLENCHED BETWEEN NATURAL TEETH. GUMS PALE.

Neck & thoracic cavities
(Pharynx, Larynx, Thyroid gland, Oesophagus, Ribs, Diaphragm, Trachea, Bronchi, Lungs, Pericardium, Heart and valves, Aorta, Coronary Arteries)

BLOOD TINGED FLUID IN PHARYNX, LARYNX, TRACHEA - THESE INFECTED. THYROID GLAND FLESHY. BRONCHI & POSTERIOR OESOPHAGOS

Abdominal & pelvic cavities
(Stomach, Large bowel, Small bowel, Mesentery, Liver, Gall Bladder, Pancreas, Spleen, Kidneys and Ureters, Bladder, Reproductive organs, Abdominal aorta)

STOMACH HOLDS A LARGE MEAL UNDIGESTED FOOD INCLUDING GREEN PEAS. INTESTINES PALE & GASSY. APPENDIX REMOVED. PANCREAS PALE.

INVESTIGATIONS PERFORMED/ITEMS PROVIDED TO POLICE.

HISTOLOGY. TOXICOLOGY - BLOOD, URINE, VITREOUS - E.M.I.T (ABC)

RESULTS

SUMMARY and INTERPRETATION SEE OVER.

CAUSE OF DEATH

1. (a) INTERNAL HAEMORRHAGE due to, or as a consequence of: _____

1. (b) CHEST INJURIES - CRUSH. due to, or as a consequence of: _____

1. (c) CRUSHED BY CARAVAN. due to, or as a consequence of: _____

1. (d) _____

2. (Other significant conditions contributing to the death, but not related to the disease or condition causing it.)

MILD HYPERTENSION.

Print name of doctor making the report: ROSEMARY ROBERSON ASHBY

Signature of doctor making the report: Rosemary Ashby

Address of doctor making the report: P.O. Box 8262
BARBARA QWD 4670

Telephone No. of doctor making the report: _____

Date of report: 30/07/2004

THORAX. RIGHT CHEST CAVITY OCCUPIED BY A MASS
 CLOTTED BLOOD, DARK, WT 3000 G COMPRESSING THE
 R. LUNG 400 G WHICH IS ATELECTATIC. THERE IS NO
 VISIBLE LACERATION - TEARING OF THE VISCERAL PLEURA OR
 LUNG TISSUE AND THE LUNG HAS NOT RUPTURED. THERE
 IS EXTENSIVE BRUISING OF THE R. PARIETAL PLEURA
 THROUGHOUT ESPECIALLY POSTERO-LATERAL ASSOCIATED
 WITH HAEMORRHAGE IN THE TISSUES OUTSIDE THE MEMBRAN
 THERE IS EXTENSIVE TEARING OF THE PARIETAL PLEURA
 IN THE VICINITY OF POSTERIOR-POSTEROLATERAL
 FRACTURING R. RIBS 6 & 7 WITH DISPLACEMENT. THERE
 IS BRUISING OF THE ANTERIOR CHEST WALL ESPECIALLY
 EXTERNAL & INTERNAL TO THE BODY OF THE STERNUM
 WHICH IS FRACTURED IN ITS UPPER THIRD. THE
 L. LUNG 800 G IS EXPANDED AND HAS HAEMORRHAG
 OEDEMA. THERE IS A MODERATE AMOUNT OF BLOOD
 TINGED FLUID IN THE L. PLEURAL SAC. DIAPHRAGM INTACT
 VERTEBRAL COLUMN AND AORTA INTACT.
 THE PERICARDIAL SAC HOLDS A MODERATE QUANTITY OF
 HEAVY BLOOD TINGED THIN LIQUID BLOOD. THE BLOOD HAS
 ORIGINATED FROM A SMALL ABRADED AREA POSTERIOR R.
 VENTRICLE - THE WALL HAS NOT BEEN PERFORATED. SUSTAINED
 DURING PERICARDIOCENTESIS IS MORE LIKELY THAN RUPTURE O
 AN ISCHAEMIC TRAUMATIC NECROSIS. HEART PALE 400 G.
 THERE IS MILD L. VENTRICULAR CONCENTRIC HYPERTROPHY
 AND ONE SMALL FOCUS OF ISCHAEMIC FIBROSIS. VALVES NORMAL
 CORONARY ARTERIES MILD ATHEROMA R & L HAS MILD TO
 MODERATE. GOOD LUMENAE, NO ACUTE OCCLUSIONS. AORTA,
 MINIMAL ATHEROMA. NO PULMONARY EMBOLUS.

ABDOMEN & PELVIS LIVER PALE 2000 G, LOBULAR PATTERN
 PROMINENT. GALL BLADDER NORMAL. ABDOMINAL AORTA INTACT
 MINIMAL ATHEROMA. SPLEEN NORMAL 170 G. NO ENLARGED
 (CONT. BACK PAGE 1).

INTERNAL. (CONT.)

FINE

ABDOMEN & PELVIS. KIDNEYS PALE. MINIMAL VERY FINE
SUBCAPSULAR GRANULARITY, 180G EACH. URETERS AND
BLADDER NORMAL. PROSTATE GLAND MILD ENLARGEMENT
BENIGN CONSISTENCY. TESTES NORMAL. ADRENAL GLAND
NORMAL. VERTEBRAL COLUMN & PELVIC GIRDLE INTACT


COMMENT THE BLOOD IN THE R. CHEST APPEARS TO HAVE
ORIGINATED FROM INTERCOSTAL BLOOD VESSELS NOT ONLY
AT THE FRACTURE SITES BUT BRUISING-CRUSHING
DAMAGE TO SOFT TISSUES. THE R. INTERNAL
MAMMARY VESSELS MAY HAVE BEEN DAMAGED BY A
STERNAL FRACTURING, BUT COULD NOT BE IDENTIFIED.
IT IS MORE LIKELY THAN NOT THAT THE BLOOD IN THE
PERICARDIAL SAC AROSE FROM A SMALL SUPERFICIAL
TEAR IN THE VISCERAL PERICARDIAL MEMBRANE DURING
PERICARDIOCENTESIS.

THERE SEEMS TO HAVE BEEN A SLOW ACCUMULATION
OF BLOOD IN THE R. PLEURAL SAC, BLOOD FINDING ITS
WAY VIA THE TORN PARIETAL PLEURAL MEMBRANE
MANY OF THE CHEST WALL SMALL BLOOD VESSELS
LIKELY TO HAVE BEEN DAMAGED-CRUSHED-DEVITALIZED
AS WELL AS THOSE AT THE FRACTURE SITES. THE
MILD HYPERTENSION INITIALLY MAY OR MAY NOT HAVE
ENCOURAGED BLOOD LOSS BUT HYPOTENSION, SHOCK
CARDIAC DECOMPENSATION WOULD SET IN AT A CRITICAL
POINT OF ACCUMULATION. THE COMPRESSED R-LUNG
WOULD IMPEDE GAS EXCHANGE.

HOSPITAL CHART-NOTES NOT AVAILABLE TILL AFTER
AUTOPSY AND I WILL READ THIS WHEN AVAILABLE TO
TRY AND GET SOME IDEA OF PROGRESS OF SIGNS,
MANAGEMENT, ETC. A QUICK PERUSAL GAVE MENTION
OF HAEMACHROMATOSIS IN THE PAST. I SAW NO EVIDENCE
OF THIS ACADEMIC IN THIS CONTEXT.

R. Aubrey

DESMOND BRAMICH



DATE OF DEATH 28 07 2004

DATE OF POST MORTEM 29 07 2004

EXTERNAL EXAMINATION

A sturdy middle aged caucasian man in a body bag in which there is some blood. The clothing is hospital grey and white under pants. The build is muscular. The abdomen is distended. HT 180 cm. The hair is short and grey but the pubic hair is slightly auburn. The eyes are grey. The body is circumcized

There is residual Rigor Mortis. The Lividity is faint and dorsal

There is a Rose motif tattoo upon the left breast

There is a surgical scar on the right lower abdomen

There is evidence of medical attention - I-V needles two left hand, one right wrist, one right Brachial Fossa. There is a CVM line in the right neck. There are two chest tubes sutured in place in the right lateral chest wall and one in the left lateral chest wall. There is an in-dwelling Bladder catheter. There are ECG pads A

The skin and mucus membranes are pale. There is fresh bruising and swelling of the tissues of the Right Chest anteriorly laterally and posteriorly. There is fresh bruising of the Left upper chest anteriorly and laterally and the Left shoulder region. There is blood tinged fluid in the mouth and nostrils and the Tongue is clenched between the front teeth. Blood stained fluid seeps from the right chest tubes upon moving the body . A Small Epigastric Punctures

INTERNAL EXAMINATION

The tissues are pale and oedematous. There is an haemorrhagic mass in the right chest cavity

HEAD

The Scalp is intact and pale. The Skull is intact. The Brain is pale I400 G otherwise normal upon routine sectioning. The teeth are natural The Tongue and gums are pale

NECK

The Cervical Vertebrae and Spinal Cord are intact. There are some small haemorrhages around the Oesophagus. The Thyroid Gland is prominent but within normal size limits. It is rather pale. The Hyoid and Larynx are intact. The Pharynx Larynx and Trachea hold blood tinged fluid

THORAX

The Right Pleural Sac contains 3000 G of dark clotted blood and a small amount of liquid blood. The Right Lung is collapsed 400g and there is no obvious rupture or tear, laceration, puncture in the Visceral Pleural Membrane covering the Lung. The Right Chest Wall is bruised boggy and haemorrhagic. There is tearing of the Parietal Pleura particularly in the mid zone postero-lateral region. There is fracturing with displacement of the Right 6 and 7 Ribs in the postero-lateral region. The Left Pleural Sac holds a moderate amount of blood tinged thin liquid. The Left Lung is expanded 800 G and shows haemorrhagic oedema upon section

There is generalized bruising of the chest wall. The Body of the Sternum is fractured through and through in its upper to mid third

The Pericardial Sac holds some heavily blood tinged thin fluid approx: 200 mL. The Heart 420 G has mild Left Ventricular Hypertrophy. The Myocardium is pale. There might be one tiny focus of ischaemic fibrosis. The Valves are normal. The R Coronary Artery has mild atheroma, the L system mild to moderate atheroma. The luminae are good and there are no acute occlusions. There is no pulmonary embolus. Upon the posterior aspect of the Right Ventricle there is a small tear in the Visceral Pericardium. This and the blood in the Pericardial Sac are at present attributed to Pericardiocentesis

There is some bruising haemorrhage upon the posterior aspect of the Oesophagus

The Diaphragm is intact

The Major Great Blood Vessels are intact. The Aorta has minimal atheroma

ABDOMEN and PELVIS

Stomach filled with undigested food inclusive of green peas. The ~~En~~ Intestines are pale and gassy and have Serosal oedema. The Appendix has been removed. The Liver 2000 G is intact and pale, The lobular pattern is a little accentuated. The Gall Bladder is normal. The Pancreas is pale

Spleen intact and normal 170 G. The Mesentery is fatty. There are no abnormal Lymph Glands

The Adrenal Glands are normal

The Kidneys are very pale. The subcapsular surface has patchy very fine granularity but is mostly smooth. The Medullary Pyramids are pale Each Kidney 180 G. The Ureters are normal also the Bladder. The Prostate Gland has a mild to moderate enlargement of benign consistency

The Testes are normal

The Aorta is intact and has minimal atheroma

The Vertebral Column and Pelvic Girdle are intact

CAUSE OF DEATH

- Ia Internal Haemorrhage
- Ib Chest Injuries - Crush
- Ic Crushed by Caravan
- 2 Mild Hypertension

INVESTIGATIONS

Histology
Toxicology Blood Urine Vitreous Humour E M I T Alcohol

COMMENT

As per FORM 8

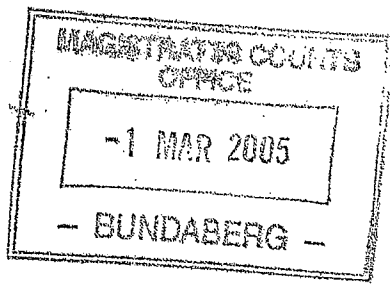
ERRATA

ATTENDING CONSTABLE C FINDLAY BUNDABERG

* DOCTORS BOYD and GUPTA SURGICAL REGISTRARS B BASE HOSPITAL

* PHONED CORONERS OFFICE TO REQUEST PERMISSION.

Handwritten signature and date: 01/08/2004



27/2/2005.

N. Lavaning, Esq.
Office of local Coroner
Bundaberg.

Dear Mr Lavaning

Re: DESMOND BRAMICH Deceased.

Thank you for yours of 17th received here 23rd.

I am trying to arrange a day with the B.B.H when I can read the hospital notes for a proper length of time and they will be available for me (!). Sort may take a little while. I did need them in haste a while back but need them for paper for fair evaluation. Unofficially, and off the cuff, it was my impression that they had not realized that Bramich was,

having a slow internal blood loss - I got
the impression that it was a case of "too
many cocks" and no one seemed to be
taking charge. Then, of course, there were
lots of rumours floating about plus
exotic impracticable diagnoses!

I hope I can achieve the notes this
coming week and that will not be too
much of a delay for you.

Yours sincerely,

Rosmary Asby.

(ASBY. R.R.).

(I often think that the Stethoscope is more
an item of jewellery rather than an
aid to diagnosis and too much reliance
is placed upon electromagnetic aids
however, that is the opinion of an ancient
R.