

28 MAY 2004

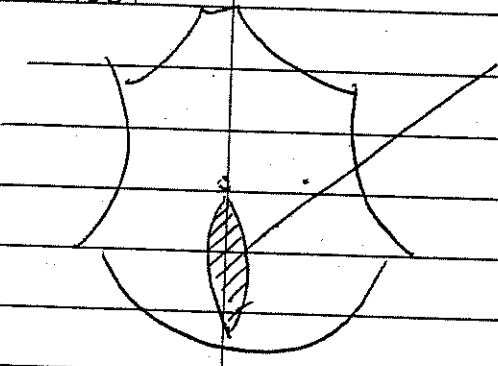
SURGICAL WARD REVIEW

Staples out -
No infection -
Secure by theme
SITED on Asymptomatic

10/6/03

SURGICAL WARD REVIEW DR PATEL

WNTS 0061



pink granulating wound
sloughs and moist +++
looks inflammatory rather than
infected
probed and hit and abdominal wall
not unresponsive
bowels working normally

continue daily dressing
return for medical review in 1/52

WNTS 0061

18 JUN 2003

SURGICAL WARD REVIEW

WNTS 0061

abdominal wound improving
granulating well
reduced in size
minimal o/c
no evidence infection

continue daily dressing
FU 2/52

daily dressing

WNTS 0061